

# Osseodensification

## Partial Extraction Therapy



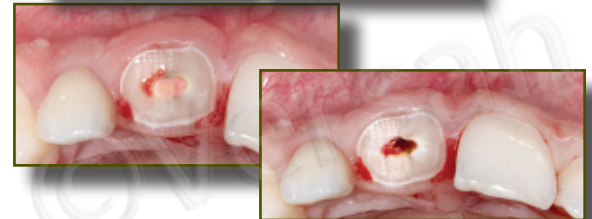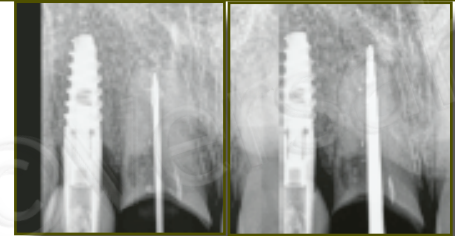
P.E.T.

Howard Gluckman, BDS, MChD, PhD

- MEASURE THE LENGTH OF THE ROOT FROM THE GINGIVAL LEVEL TO THE APEX ON THE CBCT
- DECORONATE THE TOOTH HORIZONTALLY AT THE GINGIVAL LEVEL
- USE GATES GLIDDEN BURS TO REMOVE ANY GP FILLING AND TO OPEN THE ROOT CANAL
- SECTION THE ROOT MESIODISTALLY IN A C-SHAPE WITH A SWEEPING MOTION
- REMOVE THE PALATAL ROOT SEGMENT WITH THE APEX
- PREPARE THE APICAL PORTION OF THE SHIELD AND REDUCE THE SOCKET-SHIELD TO BONE LEVEL
- CREATE A 2MM CHAMFER IN THE CORONAL SHIELD PORTION
- USE THE DENSAH® BURS TO CREATE THE IMPLANT OSTEOTOMY IN CORRECT 3D POSITION LINGUAL TO THE SHIELD
- PLACE IMPLANT 1.5 MM BELOW THE SHIELD AND FACIAL BONE CREST LEVEL
- USE BONE GRAFT TO FILL THE JUMP GAP IF NECESSARY
- CREATE CUSTOM HEALING ABUTMENT OR PROVISIONAL CROWN CONFORMING TO EXTRACTION SOCKET PERIPHERY

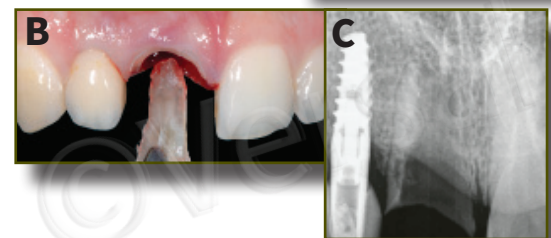
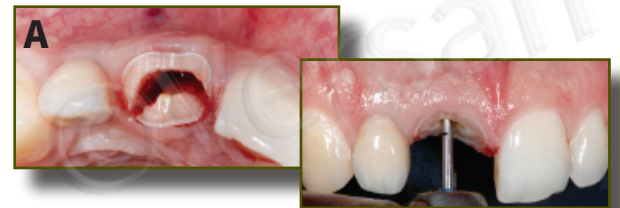### Step 1

1. Measure root length on the radiograph and from the visible gingival margin to the root apex (this can only be done if the lips are held away from the gingiva by a cotton roll or another lip retractor while taking the CBCT).
2. **Decoronate the tooth horizontally at the level of gingival.** If a post is present, the cut should be limited to the palatal portion to avoid damage to the facial root portion. Slowly cut apically in a sweeping motion, on the palatal side until the post loosens. Widen the tooth canal with Gates Glidden burs. This removes canal tissue or endodontic filling material if present. It is advised to confirm the apex has been reached with a radiograph.



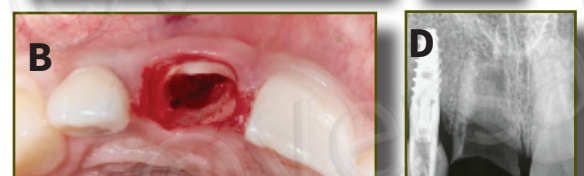
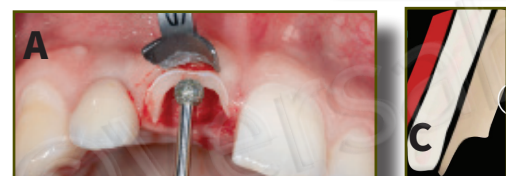### Step 2

1. Section the root mesiodistally in a C-Shape with sweeping motion that progresses the root-resection bur apically (figure A).
2. Extract the lingual root portion into the space. This is preferably done with a micro-periotome and elevator (figure B).
3. Confirm complete sectioning of the root. Any movement at the facial aspect during luxation, indicates incomplete sectioning of the root.
4. Once the palatal root portion is extracted, the root apex and endodontic filling materials should be carefully removed.
5. This is performed with the use of a round diamond. The brushing movement is done from apex to coronal direction to prevent any perforation of the apical buccal plate.
6. Complete removal of the apical portion of the root as well as all canal contents must be verified by periapical radiograph (figure C).



### Step 3

1. Reduce the socket-shield to bone level with a diamond bur while carefully reflecting the soft tissue with a gingival protector.
2. Create a 2 mm chamfer at the coronal portion of the shield. This 2 mm chamfer allows for additional prosthetic space and soft tissue seal around the implant prosthetic component. (as in figure B & C).

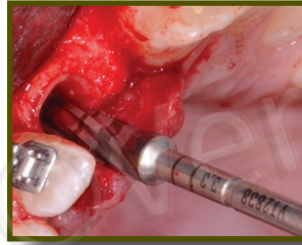


STEP 3 CONTINUED...

3. Gently probe inner dentin surface to confirm absence of mobility and take a radiograph to confirm all GP material and the root apex has been removed (as in figure D).

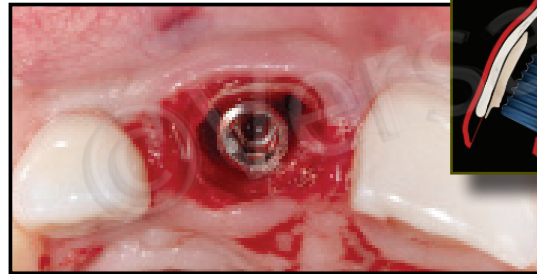
#### Step 4

**Create the implant osteotomy lingual to the prepared socket shield.** Use the Densah® Burs in increments per the implant trajectory. The Densah® Burs will densify lingually and to the apex improving bone quality and stability for the implant.



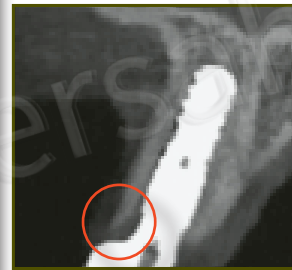
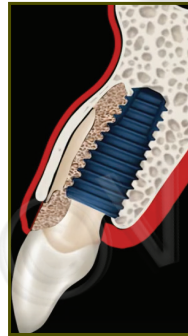#### Step 5 a

**Place implant 1.5 mm below the facial bone crest.** When possible, implant should be placed further from socket shield toward the lingual. Doing so creates the space facial to the implant to allow for tissue healing at the coronal aspect.



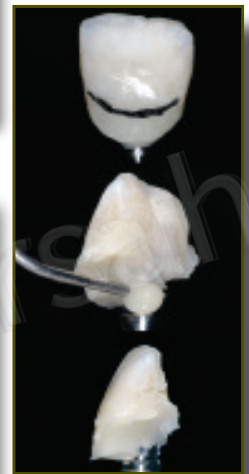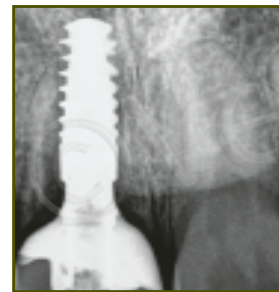#### Step 5 b

**Place bone graft** between the implant and the socket shield. Confirm bone infill with a radiograph. Bone can be placed before implant placement utilizing the Densah® Burs used in a counter clockwise (CCW) direction at 150 rpm prior to implant placement. This will ensure good bone fill all around the implant.



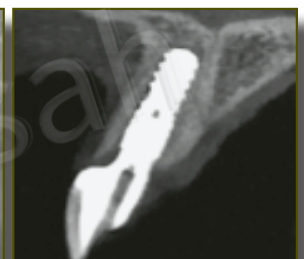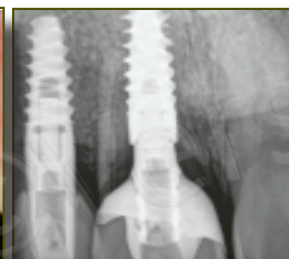
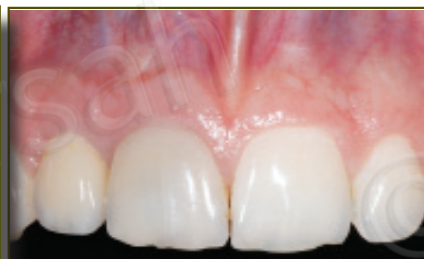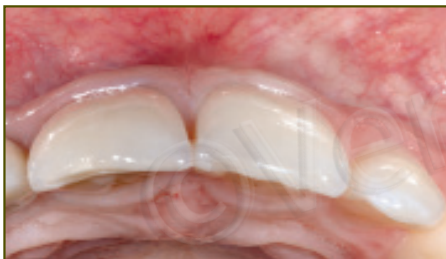#### Step 6

Custom provisional restoration. **It is vital that a custom healing abutment or provisional crown is used.** The customized abutment should conform to the extraction socket periphery and should have a significant undercut, narrowest at the implant interface, to allow for maximal soft tissue infill and avoidance of the socket- shield exposure.



#### 1 year Followup - Healing with Provisional Restoration

Confirm implant healing next to the socket shield has adequate perio-implant tissue health and bulk with maintained pupila height.



Case courtesy of Howard Gluckman, BDS, MChD, PhD