

## Case Report

# Tomographic and Clinical Findings, Pre-, Trans-, and Post-operative, of Osseodensification in Immediate Loading

Rafael Coutinho Mello Machado<sup>1</sup>, Cristiane Santos da Gama<sup>2</sup>, Sandro Henrique Batista<sup>3</sup>, Denise Rizzo<sup>4</sup>, Helder Valiense<sup>1</sup>, Ruda F. Moreira<sup>2</sup>

<sup>1</sup>Graduate Program in Dentistry at Fluminense Federal University, <sup>2</sup>Department Oral Implantology at São José College, <sup>3</sup>Graduate Program in Dentistry at Veiga de Almeida University, <sup>4</sup>Private Clinical Practice, Rio de Janeiro, Brasil

## Abstract

The advance of surgical techniques and modifications with respect to the surface and macrogeometry of dental implants, such as immediate and early loading, can help reduce the time of rehabilitation for the patient when excellent primary stability is the primary prerequisite. Starting from this principle, studies using a novel technique to replace bone-subtractive drilling have been developed to optimize the implant site. This new technique, called osseodensification, was developed by Dr. Salah Huwais and patented in 2012. The name of the procedure suggests the induction of a compression wave at the tip of specially designed drills at the point of contact. This case report suggests that the clinical and radiographic results obtained could support the hypothesis that a true gain in primary stability as well as a compaction grafting can be achieved by the use of this technique.

**Keywords:** Bone mineral density, immediate implant treatment, osseodensification, primary stability

## INTRODUCTION

The advance of surgical techniques and modifications with respect to the surface and macrogeometry of dental implants, such as immediate and early loading, can help to reduce the time of rehabilitation for the patient for whom excellent primary stability is the primary prerequisite.<sup>[1-3]</sup> The predictability of osseointegration has been increasing due to the improvement of systems to obtain better results, not only for the well-being of the patient but also to decrease the chances of surgical failure.<sup>[4-6]</sup>

In cases where the quality of the bone is Type 3 or 4,<sup>[7]</sup> the need to increase the amount of bone tissue that will be in contact with the surface of the implant becomes essential to achieve excellent primary stability and to enable immediate loading.<sup>[8,9]</sup> One possibility for optimizing this process is the modification of the surgical protocol by using the technique of undersized drilling,<sup>[1]</sup> which has been suggested in the early literature as particularly useful for the immediate loading when inserting the dental implants in low bone quality sites. However, recent studies have demonstrated that under-preparation of up to 35% of the receptor bed does not have additional effects on initial stability.<sup>[10]</sup>

Recently, studies using a new technique to replace bone subtractive drilling have been developed that will optimize the implant site. This technique is called osseodensification. It was introduced by Dr. Salah Huwais as a patented novel method in 2012.<sup>[11]</sup> It proposes the induction of a compression wave by a specially designed bur at the point of contact (bone-drill), producing a controlled bone deformation through the inherent nature of bone tissue viscoelasticity and viscoplasticity.<sup>[11-15]</sup>

This technique characteristically increases (up to three-fold) the primary stability of the implant and the percentage of bone-implant contact (BIC) as compared with the traditional subtractive drilling technique.<sup>[16,17]</sup> The main advantages of this approach are the preservation of bone volume, acceleration of the healing process due to the conservation of the bone matrix and the cells, promotion of bone tissue movement, and continuous replacement of the autogenous bone graft matrix along the surface of the dental implant.<sup>[11,14,15]</sup>

**Address for correspondence:** Prof. Rafael Coutinho Mello Machado, Av. Jornalista Ricardo Marinho, 360, Sala 245, Rio de Janeiro, Brazil. E-mail: [rafaelcoutinhodemello@yahoo.com.br](mailto:rafaelcoutinhodemello@yahoo.com.br)

### Access this article online

#### Quick Response Code:



**Website:**  
[www.cellsindentistry.org](http://www.cellsindentistry.org)

**DOI:**  
10.4103/GFSC.GFSC\_22\_18

This is an open access journal, and articles are distributed under the terms of the Creative Commons Attribution-NonCommercial-ShareAlike 4.0 License, which allows others to remix, tweak, and build upon the work non-commercially, as long as appropriate credit is given and the new creations are licensed under the identical terms.

**For reprints contact:** [reprints@medknow.com](mailto:reprints@medknow.com)

**How to cite this article:** Mello Machado RC, da Gama CS, Batista SH, Rizzo D, Valiense H, Moreira RF. Tomographic and clinical findings, pre-, trans-, and post-operative, of osseodensification in immediate loading. Int J Growth Factors Stem Cells Dent 0;0:0.

Hence, the aim of this case report is to present a clinical case of dental implant immediate loading using the technique of osseodensification to optimize the surgical site.

## CASE REPORT

A 44-year-old male with melanoderma was clinically diagnosed with a #26 root fracture with hopeless prognosis after cone-beam computed tomography (CBCT) (iCAT®, Imaging Sciences International, Hatfield, PA, USA) [Figure 1a]. The plan for the patient was dental extraction immediately followed by implant installation. This clinical case was conducted according the Declaration of Helsinki of 1975, revised in 2000. The procedure was carried out in a private clinic, where the patient signed a free and informed consent form, authorizing the rights of disclosure of the images and the case to the author of this article. We used the Case Report Guidelines (CARE, [www.care-statement.org](http://www.care-statement.org)) in this present study.<sup>[18]</sup>

## Surgical procedure

Before dental extraction, [Figure 1b] asepsis of the oral cavity (with gluconate chlorhexidine 0.12%) and extraoral skin asepsis (with gluconate chlorhexidine 0.2%) were performed. After that, local anesthesia was administered with 4% articaine and 1:100.000 epinephrine. After tooth removal, initial bone instrumentation for the osseodensification was done using a pilot drill (1.7 mm), but only to establish the correct trajectory for the final restorative abutment and for the other drills to follow. The osseodensification process was started using a Densah® Bur Kit system (Versah®, Jackson, Michigan, USA). Drilling steps were performed according to manufacturer's recommended protocol. The osseodensification drills all operated with the standardized 1200 RPM counterclockwise engine rotation with abundant saline solution irrigation.<sup>[19]</sup> The sequence of drills used was: VT1828 (2.3 mm) (Versah®, Jackson, Michigan, USA), followed by two more osseodensification drills, VT2535 (3.0 mm) and VT2838 (3.3 mm), in an attempt to install a 4.3 mm × 13 mm dental implant (INTRAOSS®, São Paulo, Brazil) [Figure 2a-d].

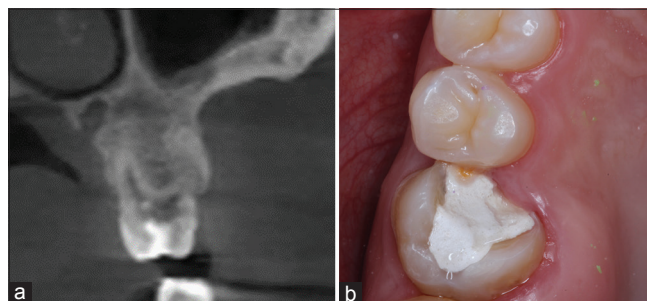
After the drilling, the patient underwent computed tomography in an attempt to gain visualization of some bone compaction in the new dental socket. In the next step, the implant was inserted in the surgical site with a torque of 45 Ncm [Figure 3a] and the mean of the resonance index ±73 implant stability quotient (ISQ) [Figure 3b] (Osstell®/W&H®, Gothenburg, Sweden) was measured. After implant placement, Xenogene Biomaterial (Lumina-Bone Porous®, Critéria Biomateriais, São Paulo, Brazil) was inserted with blood-derived growth factors in the socket gap, between the implant surface and the remaining buccal bone.

## Preparation of platelet-rich fibrin membrane

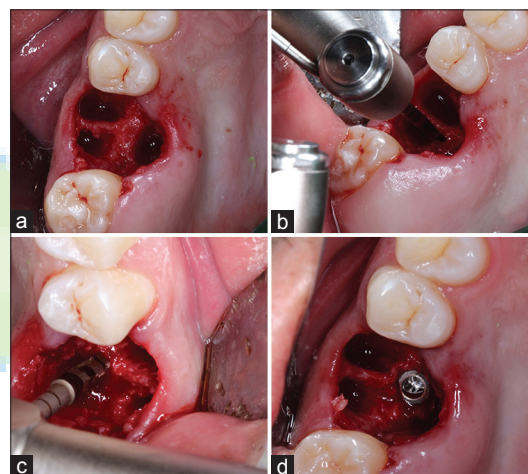
Platelet-rich fibrin (PRF) membrane was used to close the open wound in the oral cavity, preventing exposure of the bone graft. This technique was described by Mourão and Mourão. The PRF protocol has been described by several authors.<sup>[20-24]</sup>

The blood sample was collected (Labor Import®, São Paulo, Brazil) and inserted into a centrifuge with a 400 g-force vertical rotor (Kasvi, Paraná, Brazil) [Figure 4a and b].

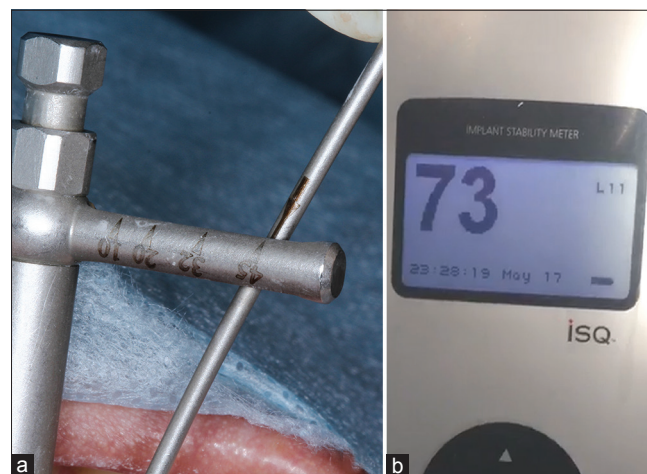After centrifugation, the PRF was collected and stored in a box (Nitinox Solutions S.L. [ref 212.029], Rio de Janeiro, Brazil), and the process of removing the exudate



**Figure 1:** (a) Computed tomography, aspect showing the resorption of the vestibular root. (b) Occlusal view of the dental element



**Figure 2:** (a) Alveolar septum appearance after use of carbide burr to eliminate granulation tissues. (b) Use of the drill 1.7 mm. (c) Use of Versah 3.0 drill. (d) Installation of the implant in the surgical site




**Figure 3:** (a) The dental implant insertion with 45 Ncm. (b) Analysis with Osstell marking resonance index 73 implant stability quotient



from the membrane. After finishing the production of the PRF, it was installed in the lower part of a  $4.5 \times 6 \times 3.5$  abutment (INTRAOSS®, São Paulo, Brazil) with a posterior collagen membrane (Critéria®, São Paulo, Brazil) [Figure 5a]. With this, the PRF was exposed to the oral cavity in contact with the provisional crown [Figures 5b and 6].

### Tomographic evaluation

The radiographic evaluation was performed through CBCT examinations at three surgical stages (preoperative, transoperative, and immediately after implant installation). The region of the procedure (left jaw) contained cancellous bone. After qualitative analysis of the axial view [Figure 7a-c], a suggestive densification was evident [Figure 7b] around the new surgical site, created by osseodensification. In the coronal view as well [Figure 8a-c], a suggestive image of corticalization was present around the surgical site, different from what can typically be observed in a natural dental socket after exodontia [Figure 8b].

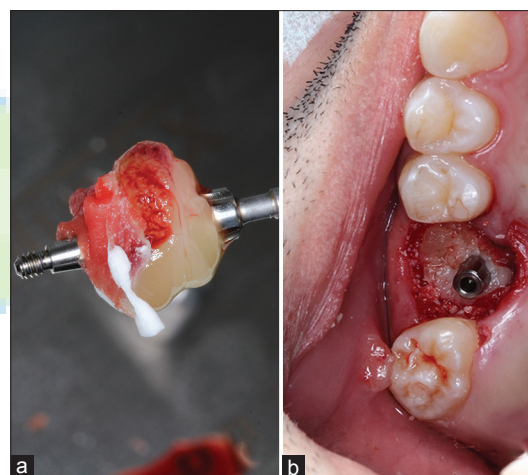


**Figure 4:** (a) Appearance after confection of the concentrate of growth factors from the blood sample. Serum, Clot/Platelet-rich fibrin, Buffy Coat zone, Red Blood Cells. (b) Modification of the original image using Fireworks software (Adobe - California, United States) evidencing the phases of the division in the blood-derived growth factors

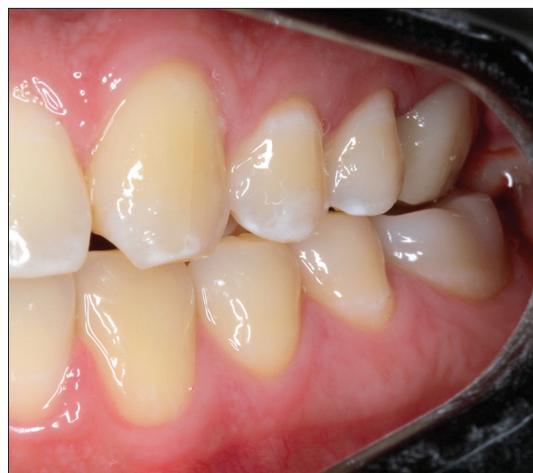### DISCUSSION AND CONCLUSION

Immediate loading is a viable treatment option. The main advantage of this approach is the reduction of treatment time and esthetic-functional rehabilitation.<sup>[25,26]</sup> The search for immediate loading is considered multifactorial where the primary prerequisite is good primary stability.<sup>[3,27-29]</sup> One of the alternatives presented by the scientific community was the development of osseodensification, which qualifies as a possible technique in the search for stability. There is a publication where osseodensification is misrepresented. This specific study claimed that there is no real gain of implant stability with osseodensification at the time of implant installation compared with standardized milling.<sup>[30]</sup> In this murine animal model study, osseodensification was not used, so describing this article as a finding that osseodensification does not increase implant stability is not valid. The author needs to point out the fact that this article is not related to osseodensification because it was not used in his study process.

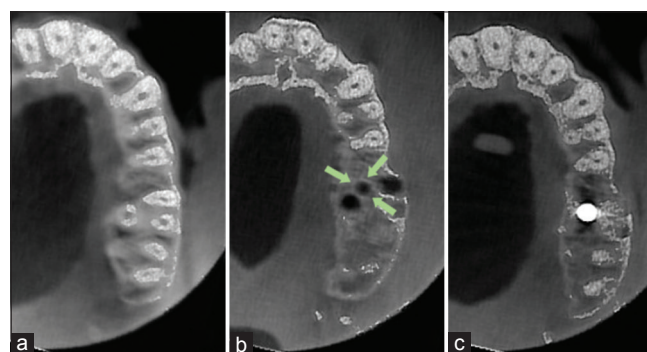
In the present work, it was possible to clinically observe a gain in primary stability. Despite the fact that the literature



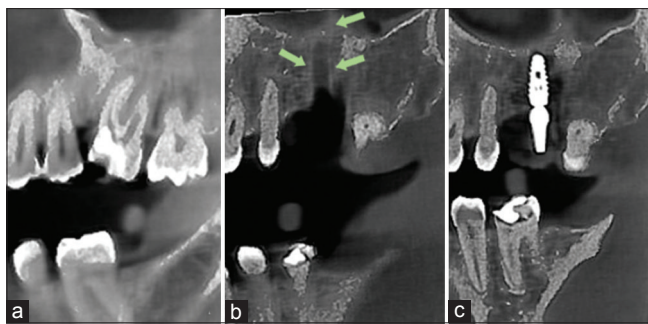
**Figure 5:** (a) Image showing protective barrier using platelet-rich fibrin and collagen membrane in the abutment. (b) Clinical aspect of the abutment installed with the protective barrier positioned



**Figure 6:** The clinical aspect of the case with the provisional crown



**Figure 7:** (a) Axial view of the region of the surgical procedure (preoperative). (b) Axial view of the region of the surgical procedure (trans-operative) evidencing the corticalization of the surgical alveolus by the osseodensification technique. (c) Axial view of the surgical procedure (postimplant installation)



**Figure 8:** (a) Coronal view of the surgical procedure region (preoperative). (b) Coronal view of the region of the surgical procedure (trans-operative) showing corticalization of the surgical alveolus by the osseodensification technique. (c) Coronal view of the surgical procedure region (postimplant installation)

reports evidence for the presence of densification in computed microtomography.<sup>[11]</sup> In this case, CBCT images demonstrated clearly the densification of the bony walls after instrumentation using osseodensification burs.

In the present case, the osseodensification served to increase primary stability and enhance BIC. The dental socket in the region where the implant was installed (posterior of the maxilla) initially presented low bone density, but, with the aid of the densifying burs, the implant was adequately placed and with a sufficient stability, reflected in the ISQ ( $\geq 70$ ), which is an indicator for an immediate provisional protocol.<sup>[28,29]</sup>

Exposure of the implant to the oral cavity is always a possibility in clinical practice after implant placement. Hence, techniques to avoid exposure of the graft to the oral cavity have been used, for example, the use of connective tissue grafts and keratinized tissue grafts. These techniques have low infection rates, and there is no rejection; however, they require a highly skilled dental surgeon and may increase surgical morbidity due to the need for a donor site.

However, a good option – which was used in this case – was the use of a blood-derived growth-factor membrane, in an attempt to reduce postoperative surgical morbidity for the patient. This modality has become a viable option when a better adaptation occurs around the dental socket, and this facilitates the installation of this material, as well as potential wound healing related to soft tissues. It is an easily obtained and low-cost membrane, compared with other materials such as the collagen membrane. In addition, as has already been shown, the PRF membrane slowly releases significant amounts of growth factors (transforming growth factor  $\beta 1$ , platelet-derived growth factor-AB, vascular endothelial growth factor) and thrombospondin-1 for at least several days.<sup>[19,20,22,23,31]</sup>

The present case report aims to stimulate further randomized and controlled clinical studies on the use of the osseodensification technique. The evaluation of density before the dental implant placement is recommended, due to the potential for production of artifacts in tomographic images. We have also obtained a better scientific understanding of the gain in stability with the

technique, as already described in other (*in vitro* and *in vivo*) studies.

In this case, the clinical and radiographic results obtained, following the initial planning, direct the dental surgeon to accept the hypothesis of the real gain in primary stability achieved with the use of the osseodensification technique. It is a new bone instrumentation technique that relies on bone tissue preservation and compaction-autografting, and as any new treatment modality, it may require a learning curve to achieve reproducible success.

## Financial support and sponsorship

Nil.

## Conflicts of interest

There are no conflicts of interest.

## REFERENCES

- Trisi P, Berardi D, Paolantonio M, Spoto G, D'Addona A, Perfetti G. Primary stability, insertion torque, and bone density of conical implants with internal hexagon: Is there a relationship? *J Craniofac Surg* 2013;24:841-4.
- Giro G, Tovar N, Marin C, Bonfante EA, Jimbo R, Suzuki M, *et al.* The effect of simplifying dental implant drilling sequence on osseointegration: An experimental study in dogs. *Int J Biomater* 2013; 2013:230310.
- Javed F, Romanos GE. The role of primary stability for successful immediate loading of dental implants. A literature review. *J Dent* 2010;38:612-20.
- Jimbo R, Janal MN, Marin C, Giro G, Tovar N, Coelho PG, *et al.* The effect of implant diameter on osseointegration utilizing simplified drilling protocols. *Clin Oral Implants Res* 2014;25:1295-300.
- Jimbo R, Giro G, Marin C, Granato R, Suzuki M, Tovar N, *et al.* Simplified drilling technique does not decrease dental implant osseointegration: A preliminary report. *J Periodontol* 2013;84:1599-605.
- Sarendranath A, Khan R, Tovar N, Marin C, Yoo D, Redisch J, *et al.* Effect of low speed drilling on osseointegration using simplified drilling procedures. *Br J Oral Maxillofac Surg* 2015;53:550-6.
- Lekholm U, Zarb G. Patient selection and preparation. In: Branemark PI, Zarb GA, Albrektsson T, editors. *Tissue-Integrated Prostheses: Osseointegration in Clinical Dentistry*. Chicago, IL: Quintessence; 1985. p. 199-209.
- Seeman E, Delmas PD. Bone quality – The material and structural basis of bone strength and fragility. *N Engl J Med* 2006;354:2250-61.
- Summers RB. A new concept in maxillary implant surgery: The osteotome technique. *Compendium* 1994;15(2):152, 154-6, 158 passim; quiz 162.
- Degidi M, Daprile G, Piattelli A. Influence of underpreparation on primary stability of implants inserted in poor quality bone sites: An *in vitro* study. *J Oral Maxillofac Surg* 2015;73:1084-8.
- Huwais S, Meyer EG. A novel osseous densification approach in implant osteotomy preparation to increase biomechanical primary stability, bone mineral density, and bone-to-implant contact. *Int J Oral Maxillofac Implants* 2017;32:27-36.
- Friberg B, Ekestubbe A, Mellström D, Sennerby L. Brånemark implants and osteoporosis: A clinical exploratory study. *Clin Implant Dent Relat Res* 2001;3:50-6.
- Friberg B, Ekestubbe A, Sennerby L. Clinical outcome of Brånemark system implants of various diameters: A retrospective study. *Int J Oral Maxillofac Implants* 2002;17:671-7.
- Lopez CD, Alifrag AM, Torroni A, Tovar N, Diaz-Siso JR, Witek L, *et al.* Osseodensification for enhancement of spinal surgical hardware fixation. *J Mech Behav Biomed Mater* 2017;69:275-81.
- Trisi P, Berardini M, Falco A, Podaliri Vulpiani M. New osseodensification implant site preparation method to increase bone density in low-

- density bone: In vivo evaluation in sheep. *Implant Dent* 2016;25:24-31.
16. Lahens B, Neiva R, Tovar N, Alifrag AM, Jimbo R, Bonfante EA, *et al.* Biomechanical and histologic basis of osseodensification drilling for endosteal implant placement in low density bone. An experimental study in sheep. *J Mech Behav Biomed Mater* 2016;63:56-65.
17. Alifrag AM, Lopez CD, Neiva RF, Tovar N, Witek L, Coelho PG. Temporal osseointegration: Early biomechanical stability through osseodensification. *J Orthop Res* 2018; Epub ahead of print.
18. Riley DS, Barber MS, Kienle GS, Aronson JK, von Schoen-Angerer T, Tugwell P, *et al.* CARE guidelines for case reports: explanation and elaboration document. *J Clin Epidemiol.* 2017; 89: 218-35.
19. Gehrke SA, Sardá JA Jr., Pérez-Albacete Martínez C, Ramirez Fernandez MP, Maté Sánchez de Val JE, Calvo-Guirado JL. The influence of drill length and irrigation system on heat production during osteotomy preparation for dental implants: An ex vivo study. *Clin Oral Implants Res* 2016;4:1-7.
20. Mourão C, Mourão N. Platelet-rich fibrin membrane in immediate dental implant loading. *Dent Press Implantol* 2015;9:104-9.
21. Dohan DM, Choukroun J, Diss A, Dohan SL, Dohan AJ, Mouhyi J, *et al.* Platelet-rich fibrin (PRF): A second-generation platelet concentrate. Part I: Technological concepts and evolution. *Oral Surg Oral Med Oral Pathol Oral Radiol Endod* 2006;101:e37-44.
22. Dohan Ehrenfest DM, Bielecki T, Jimbo R, Barbé G, Del Corso M, Inchingolo F, *et al.* Do the fibrin architecture and leukocyte content influence the growth factor release of platelet concentrates? An evidence-based answer comparing a pure platelet-rich plasma (P-PRP) gel and a leukocyte- and platelet-rich fibrin (L-PRF). *Curr Pharm Biotechnol* 2012;13:1145-52.
23. Dohan D, Del Corso M, Diss A, Mouhyi J, Charrier JB. Three dimensional architecture and cell composition of a Choukroun's platelet-rich fibrin clot and membrane. *Curr Pharm Biotechnol* 2012;13:546-55.
24. De Andrade L, Leite L, De Melo Silva F, De Brito Resende RF, Guedes De Uzeda MJ. The use of platelet-rich fibrin concentrate in tissue healing and regeneration in dentistry. *Int J Growth Factors Stem Cells Dent* 2018;1:23-6.
25. Nemcovsky CE, Artzi Z, Moses O. Rotated palatal flap in immediate implant procedures. Clinical evaluation of 26 consecutive cases. *Clin Oral Implants Res* 2000;11:83-90.
26. De Bruyn H, Vandeweghe S, Ruyffelaert C, Cosyn J, Sennerby L. Radiographic evaluation of modern oral implants with emphasis on crestal bone level and relevance to peri-implant health. *Periodontol* 2000 2013;62:256-70.
27. Zhang S, Wang S, Song Y. Immediate loading for implant restoration compared with early or conventional loading: A meta-analysis. *J Craniomaxillofac Surg* 2017;45:793-803.
28. Milillo L, Fiandaca C, Giannoulis F, Ottria L, Lucchese A, Silvestre F, *et al.* Immediate vs. non-immediate loading post-extractive implants: A comparative study of implant stability quotient (ISQ). *Oral Implantol (Rome)* 2016;9:123-31.
29. Norton MR. The influence of low insertion torque on primary stability, implant survival, and maintenance of marginal bone levels: A closed-cohort prospective study. *Int J Oral Maxillofac Implants* 2017;32:849-57.
30. Wang L, Wu Y, Perez KC, Hyman S, Brunski JB, Tulu U, *et al.* Effects of condensation on peri-implant bone density and remodeling. *J Dent Res* 2017;96:413-20.
31. Barros Mourão CF, Gheno E, Lourenço ES, Barbosa Rd, Kurtzman GM, Javid K, *et al.* Characterization of a new membrane from concentrated growth factors associated with denatured Albumin (Alb-CGF) for clinical applications: A preliminary study. *Int J Growth Factors Stem Cells Dent* 2018;1:64-9.

