

New Paradigm Shift in Feline Dental Implants in Maxillary Alveolar Osteitis Treatment with Osseodensification



**Rocco E Mele,
DVM**



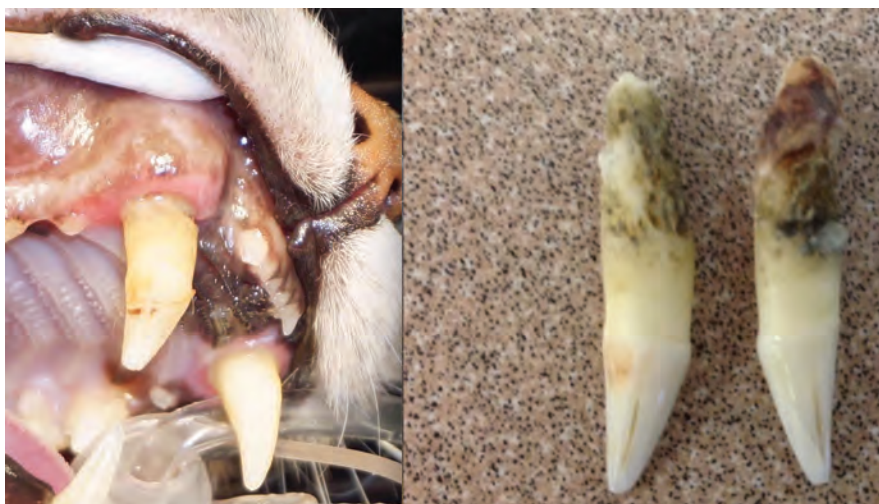**Gregori M
Kurtzman DDS
MAGD DICOI**

Introduction

Clinical applications of feline dental implantology, and more generally, applications in companion animals, have been lacking in the veterinary literature. However, the science behind dental implantology is sound and has been successfully utilized in human dentistry for over 50 years.

As with any treatment option, dental implants should be subjected to the same level of scrutiny as other treatment modalities. However, being a relatively new area of veterinary dentistry, long-term clinical success of dental implants has not been established in cats. Owners need to be made aware of this and the importance of periodontal maintenance (home care) prior to obtaining informed consent. Also, only experienced and well-trained clinicians with a sound knowledge of the principles and practice of dental implantology should embark into this field. Treatment planning for a dental implant is no different than planning for any oral surgical procedure. Before any diagnosis or treatment plan is formulated, it is essential that an intraoral examination, including a complete oral health assessment, be performed under general anesthesia.

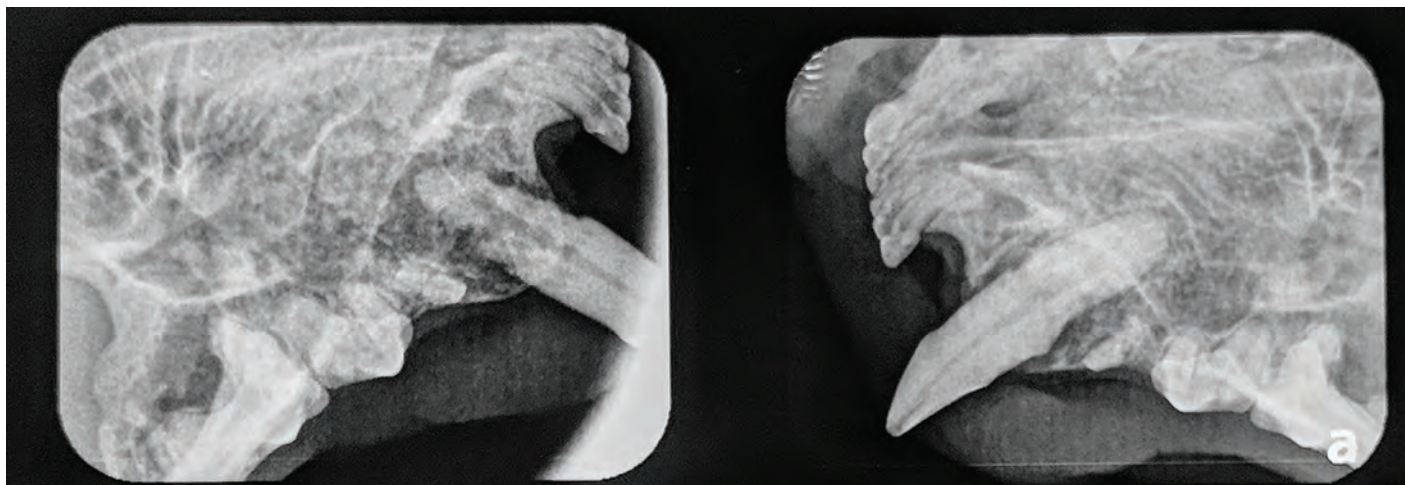
When dental implants are being considered as a treatment option, radiographs are critical in treatment planning to evaluate the affected tooth and the surrounding bone and anatomical structures. If available, computed tomography can be utilized to complete a diagnostic and treatment plan. Unfortunately, computed tomography is not available to most general practitioners and some veterinary dentists. The cases discussed



in this article suggest dental implants are an option for restoring feline patients to full oral function. Two cases of extracted maxillary canines, immediate placement of dental implants, and subsequent restoration with prosthetic crowns are discussed.

Case 1

A 5-year-old neutered male Manx cat weighing 5.2 kg was referred for evaluation of blood coming from the mouth. Initial oral examination noted bilateral maxillary canine (104;204) extrusion with osseous proliferation and a underlying periodontitis. A preliminary diagnosis Alveolar Osteitis (AO) was made. (Figure 1) The teeth were painful when touched during conscious examination. Radiographs were taken to confirm the initial diagnosis. (Figure 2)



All treatment options were presented and discussed with the pet's owner. These included: (1) surgical extraction, with socket debridement, curettage and socket augmentation with a allograft. (2) careful surgical extraction (preserving labial plate) with immediate placement of an endosseous implant, an option that would only be possible if the labial alveolar process and palatal cortical plate were intact and primary implant stability could be attained. Option (3) would involve placement of a prosthetic restoration following a healing and osseointegration phase. After discussion with the pet's owner of the advantages and disadvantages of available treatment options, he decided to pursue extraction and immediate implant placement

Surgical Phase

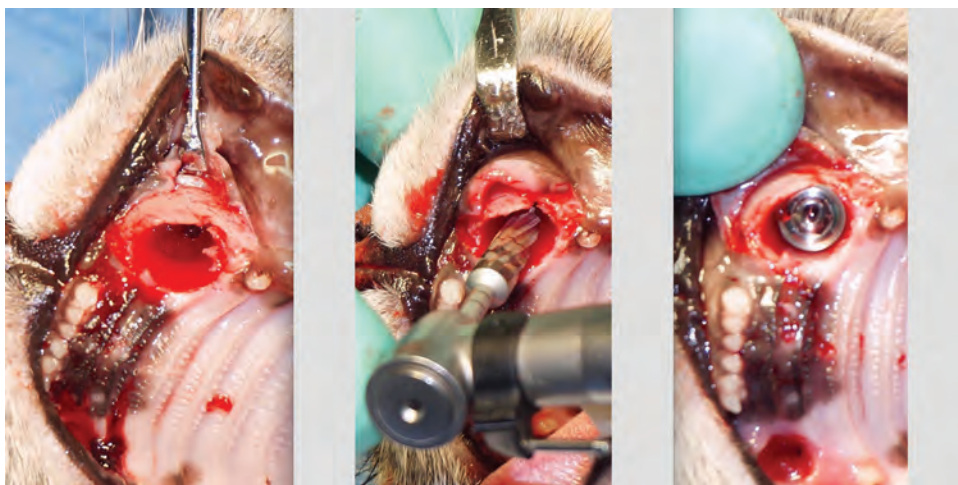
Prior to the surgical appointment, venous blood was drawn and a complete blood count and serum biochemistry profile were tested to check the patient's general health.

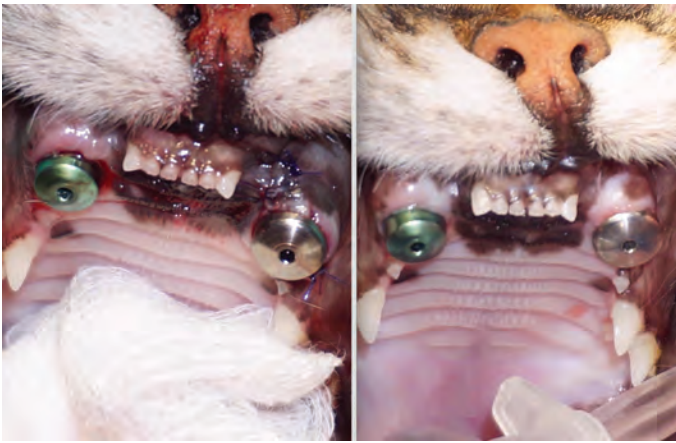Patient was premedicated with Atropine sulfate (MWI Veterinary Supply, Boise, Idaho) 0.01 mg/kg subcutaneously and Acepromazine (MWI Veterinary Supply) 0.02 mg/kg subcutaneously. An intravenous catheter was placed and lactated Ringer's solution was started at a rate of 3 mL/kg/h. General anesthesia was induced by mask with Sevoflurane (MWI Veterinary Supply). Intubation with a cuffed endotracheal tube was completed, and anesthesia was maintained at a vaporizer setting of 3% and oxygen flow of 1 L per minute. A bilateral infraorbital nerve block was administered with 0.5%

Bupivacaine (Benco Dental, Tucson, Arizona) 0.1 ml per site and Buprenorphine (MWI Veterinary Supply) 0.01 mg/kg IV following General Anesthetic Protocol (GAP).

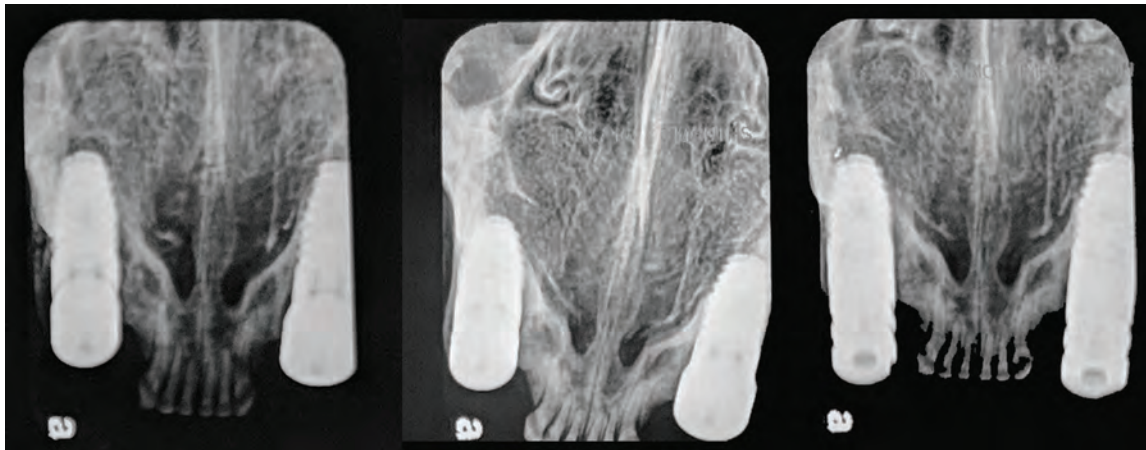
Oral examination was completed on the anesthetized patient, and digital intraoral radiographs were obtained. Notice bilateral canine root resorption and super eruption (tooth extrusion). Also areas of alveolar rarefying osteitis that will cause increase bone production moving away from the inflammation to buttress the alveolar bone. Buttressing of the alveolar bone creates a ideal site for initial stability of a immediate implant.¹

An intrasulcular horizontal releasing incision was made, and a full-thickness mucoperiosteal envelope flap was elevated to evaluate the labial alveolar process of the maxillary bone around the tooth being treated. Teeth 104 and 204 were atraumatically extracted to avoid any further damage to the alveolar bone. Socket debridement was performed utilizing a curette and copious lavage with sterile saline. (Fig 3 left)





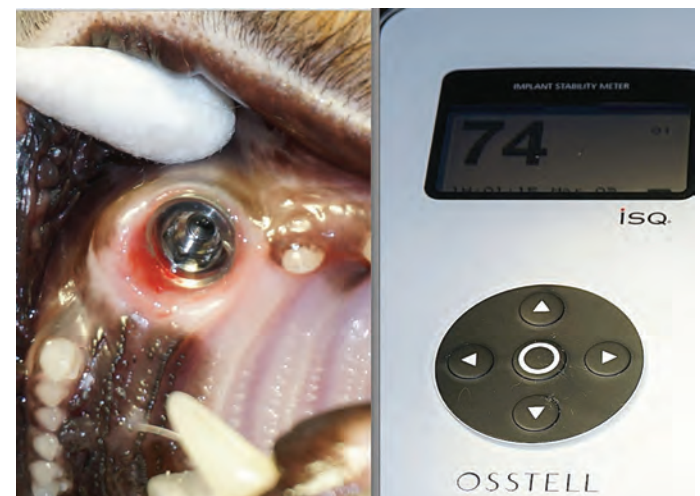
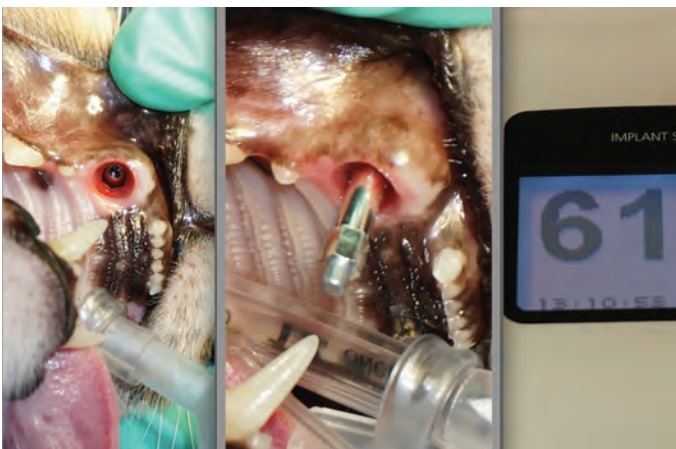5.7 mm 10 mm OCO implants (OCO Biomedical, Albuquerque, New Mexico) were inserted subcrestally with a final insertion torque of 50 Ncm.(Figure 3 right). Healing abutments were placed into the implants. Horizontal mattress sutures were placed using Securocyl, a synthetic absorbable Polyglycolide-co-caprolactone (Securos Surgical, Fiskdale, Massachusetts) to oppose the gingival tissue to the healing abutments. (Figure 4 left) This technique will develop a healthy tissue emergence profile. Recovery was uneventful and the patient was discharged with postsurgical instructions the same day. Amoxicillin/Clavulanic acid (Clavamox, Zoetis, Parsippany, New Jersey) (62.5 mg orally every 12 hours) and Buprenorphine (0.01 mg/kg orally every 12 hours for 5 days) was dispensed.



Socket osteotomy was accomplished with an osseodensification drilling protocol known as compaction auto-grafting, utilizing Densah Burs (Versah LLC, Jackson, Michigan) which compresses the osteotomized alveolar bone increasing its density. The burs utilized to achieve this rotate counterclockwise at 800 to 1200 rpm, compacting but does not cut bone. (Figure 3 middle). This technique has shown to yield better primary stability and superior bone-to-implant contact when the implant is inserted.²⁻⁵ Socket measurements (periodontal probing and intraoral radiographs) were taken and

Uncovering and Restoration Phase

Three months after implant placement, the patient returned for the start of the restorative phase and it was noted that the gingival tissues conferring the implant site were not inflamed (Figure 4 right) A similar anesthetic protocol was administered and intraoral radiographs were obtained to verify osseointegration. (Figure 5)


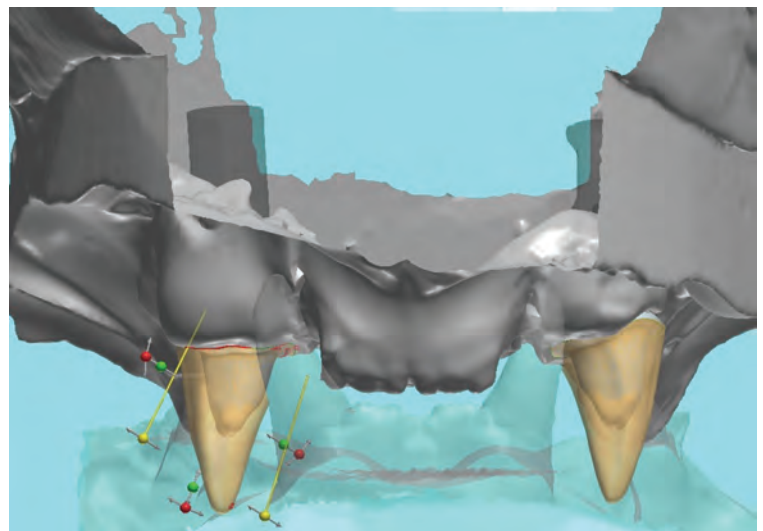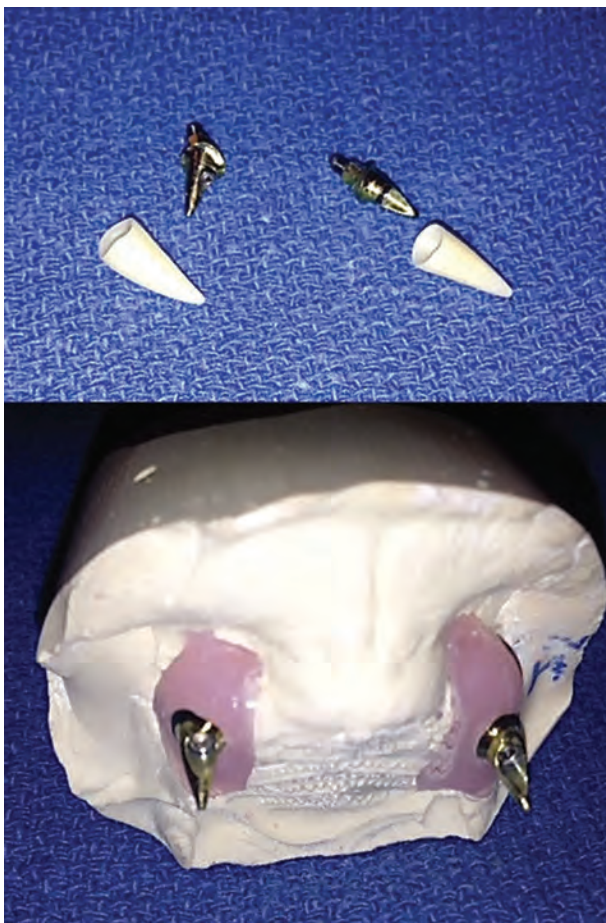


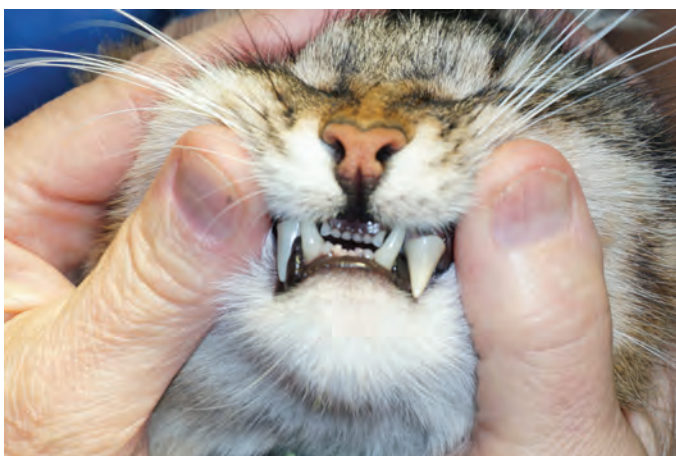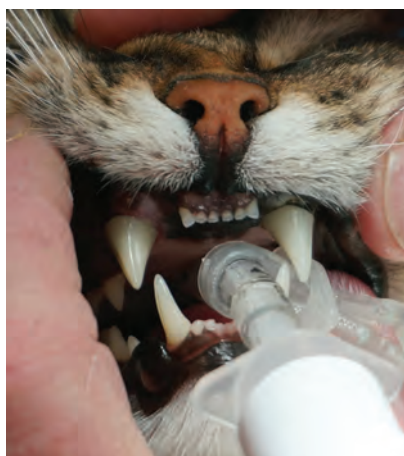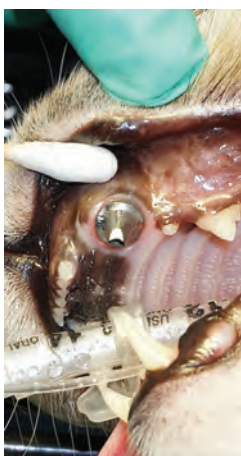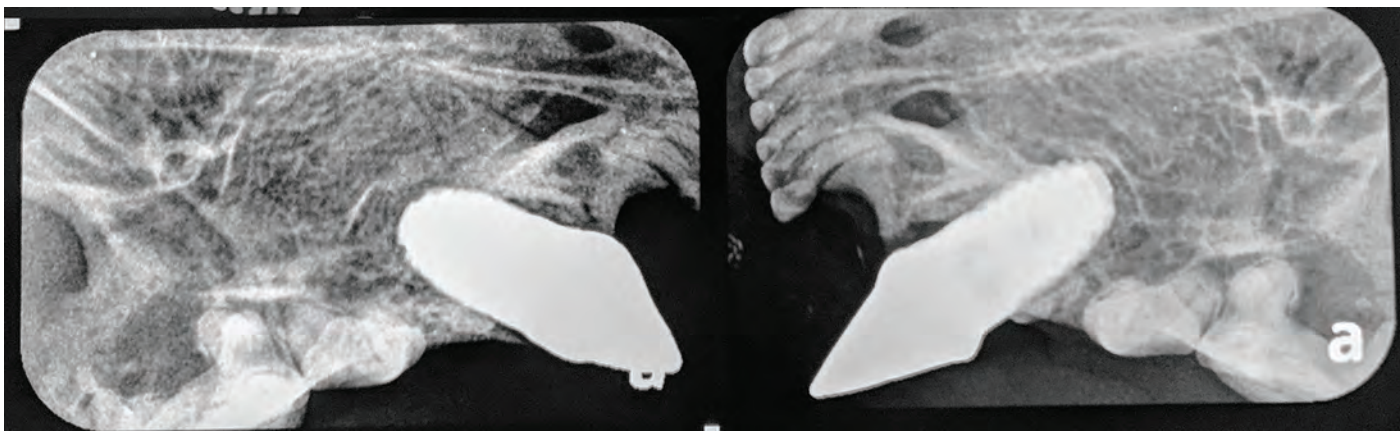
The maxillary canine (#104) healing abutment was removed at 3 months and the final implant stability quotient (ISQ) (Osstell ISQ, Osstell USA, Columbia, Maryland) was recorded at 61. (Figure 6) The same procedure was completed on the maxillary canine (#204) and the final (ISQ) was recorded at 74. (Figure 7) Implant stability quotient is the value on a scale of 1 to 100, which indicates the level of stability and osseointegration in dental implants. Implant stability quotient values are obtained using resonance frequency analysis. Higher values indicate greater stability. The acceptable stability range is considered to be between 55 and 85 ISQ. Vinyl Polysiloxane (VPS) (Valuline VPS wash, Benco Dental, Tucson, Arizona) impressions were obtained. The impression abutment was detached and a healing abutments were placed back into the implant to maintain the tissue emergence profile. It is crucial to develop and maintain healthy keratinized tissue around the implant to have stable soft tissue long term. This aids in minimizing bone resorption and inflammatory reaction around the prosthetics under function.^{6,7}

The VPS impressions were sent to the dental laboratory, and a soft tissue stone model was created with the implant analog

within the model and scanned to create a virtual model. The final components, a custom anodized metal abutment and a solid zirconia crown, were designed digitally and CAD/CAM milled. (Figures 8, 9, 10)

One month after impressions were made, the patient returned for delivery of the final restorative components. The patient was anesthetized with the same protocol utilized in the prior procedures. Intraoral radiographs were obtained to verify the proper seating of the abutments to the implants. (Figure 11) After verification, the abutment screws were hand tightened and checked with the torque wrench (20-25 Ncm) as per manufacturer's recommendation. Teflon tape was placed over the abutment screws to seal the screw access holes in screw-retained implant restorations and prevent cement from filling the screw's hex. (Figure 12) This product can be found in any hardware store. Traditionally, a cotton pellet has been used for this purpose, but this may harbor bacteria over time and it has been replaced by Teflon tape in human implant treatment. It also simplifies removal if you need to reenter the screw hole to remove or retighten the screw. Teflon tape can also be utilized



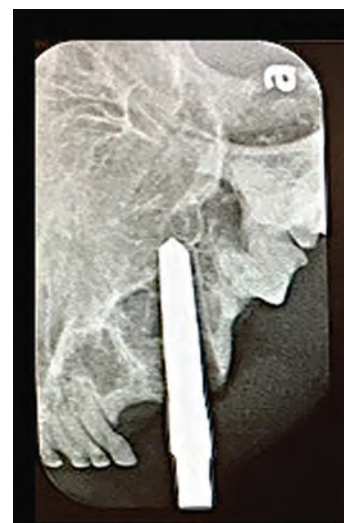
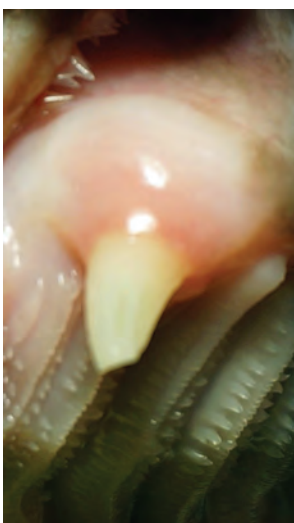
as retraction cord and to isolate teeth during cementation. The zirconia crowns were cemented to the abutments. (Figure 13) The occlusion was checked with the endotracheal tube removed to look for any abnormal contacts with the prosthetic crown.

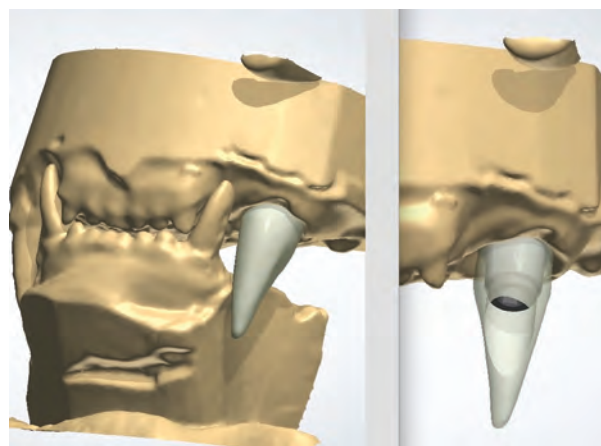
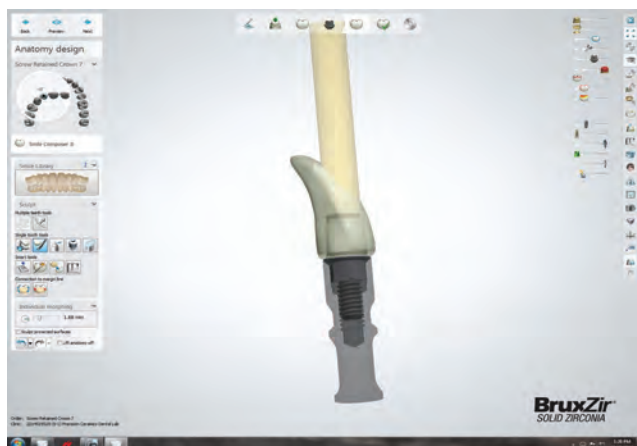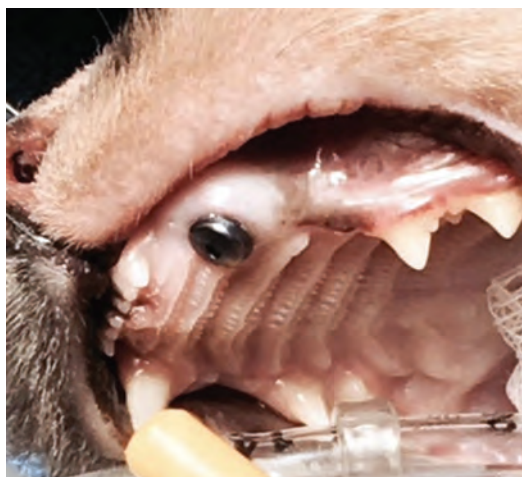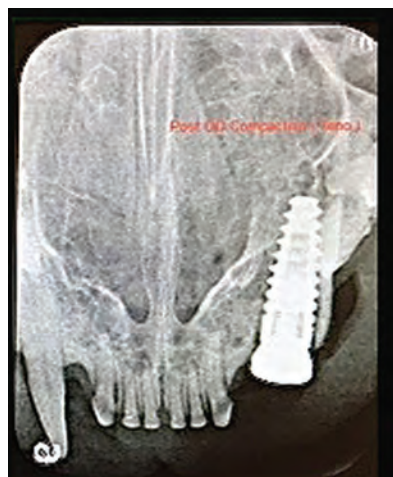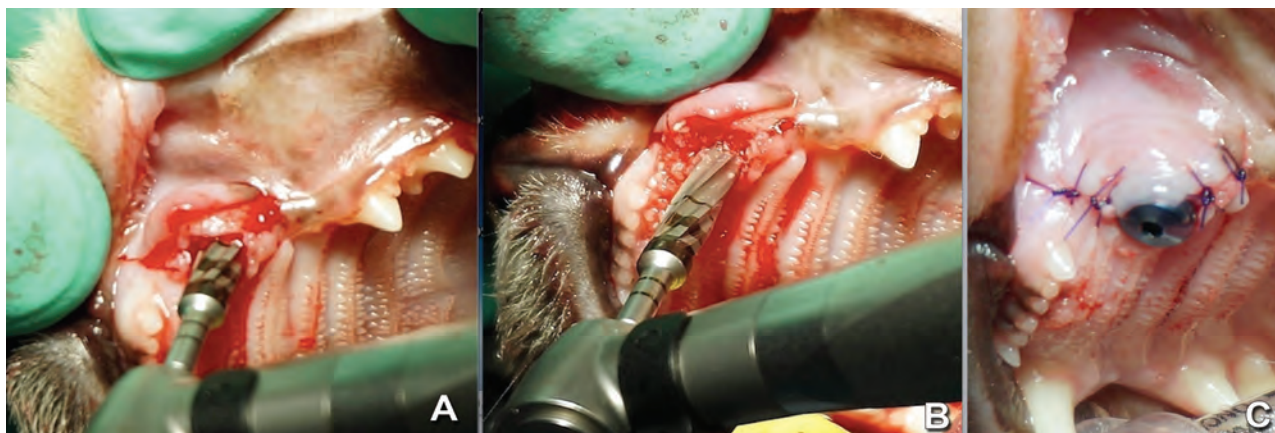
The patient was seen 10 months after restoration, demonstrating the exceptional results with non-inflamed gingiva noted surrounding the implant restoration. The same observation was observed at a recall appointment 36 months after restoration. (Figure 14) Standard implant home care instructions as described with the previous case were given to the pet's owner.

Case 2

A 6 -year-old F/S DLH cat weighing 5 kg was referred for evaluation a complicated crown fracture of a maxillary canine (#204) On initial examination the tooth appeared to be solid however there was significant alveolar enlargement that would indicate some inflammatory changes in the alveolus preliminary diagnosis of Alveolar Osteitis was made. (Figure 15) The tooth was not painful when touched during conscious examination.



All treatment options will be presented and discussed with the pet's owner after a careful oral exam and dental radiographs were completed under a general anesthetic. Do to the changes in socket morphology (buccal/palatal) RCT was given a guarded prognosis. Treatment options: (1) surgical extraction. (2) surgical extraction maintaining the bony architecture and immediate implant placement. Owner chose the later only if



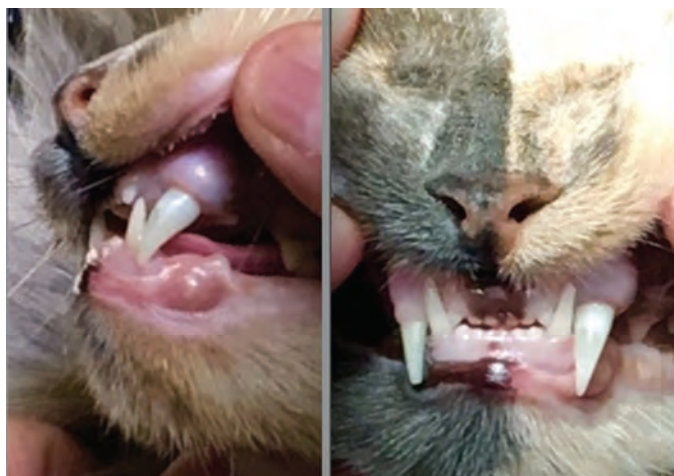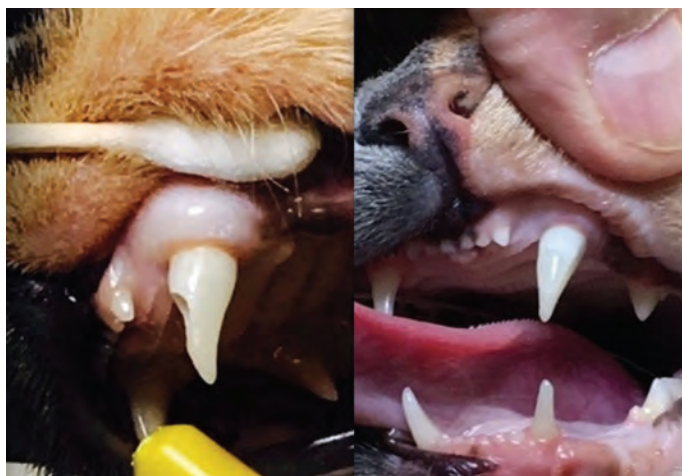the extraction site was maintained and support the implant. Extraction and immediate dental implant placement can also be problematic. However, in the authors' experience, implant placement is less problematic with fewer potential complications.

Surgical Phase

Prior to the surgical appointment, venous blood was drawn and a complete blood count and serum biochemistry profile were

tested to check the patient's general health. As with Case1 the same General Anesthetic Protocol (GAP) was utilized.

An intrasulcular vertical releasing incision was made, and a full-thickness mucoperiosteal flap was elevated to evaluate the labial alveolar process of the maxillary bone around the tooth being treated. Tooth # 204 was atraumatically extracted to avoid any further damage to the alveolar bone. Socket debridement was performed utilizing a curette and copious lavage with sterile saline. Post surgical extraction radiographs were completed to evaluate



the socket shape and obtain some accurate measurements. (Figure 16) The socket osteotomy was prepared with a new drilling protocol. Unlike traditional drilling technique osseodensification does not excavate bone tissue. Bone tissue is compacted and auto-grafted outwardly and apical direction. The Densah Bur is rotated at high speeding a reversed, non cutting direction with external irrigation. (Figure 17 A and B) A strong dense layer of bone is formed along the walls and base of the osteotomy. Dense compact bone produces stronger purchase for the dental implant and facilitates faster healing.²⁻⁵ A 4mm X 10mm OCO endosseous dental implant was placed sub-crestal. A tissue healing abutment was attached to the implant and the vertical releasing flap was closed. (Figure 17 C) A radiograph was taken which demonstrated some minor gaps between the implant and socket wall in the crestal portion of the site. (Figure 18)

Recovery was uneventful and the patient was discharged with postsurgical instructions the same day. Amoxicillin/Clavulanic acid (62.5 mg every 12 hours) and Buprenorphine (0.01 mg/kg orally every 12 hours for 5 days) were dispensed.

Uncovering and Restoration Phase

Three months after implant surgery, the patient was reevaluated for soft tissue healing and implant osseointegration. (Figure 19) Anesthetic protocol was used as described previously. Dental radiographs were obtained and evaluated. Implant stability and integration were determined to be adequate. (Figure 20) The healing abutment was removed. (Figure 21) VPS impressions were obtained as in Case 1. The healing abutment was replaced into the implant to maintain the tissue emergence profile development. It is crucial to develop and maintain healthy keratinized tissue around the implant to have stable soft tissue long term. This aids in minimizing bone resorption and inflammatory reaction around the prosthetics under function.^{6,7}

The VPS impressions were sent to the dental laboratory, and a soft tissue stone model was created with the implant analog within the model and scanned to create a virtual model (Figures

22, 23) The final components a custom metal abutment and a solid zirconia crown, were designed digitally and CAD/CAM milled.

One month after the impressions were made, the patient returned for delivery of the prosthetic crown. A similar anesthetic protocol was utilized. The tissue healing abutment was removed and the emergence profile evaluated. The occlusion was checked with the endotracheal tube removed to look for any abnormal contacts with the prosthetic crown. The abutment/crown screw was tightened to 25 Ncm and the access hole was filled with a composite restorative material and light cured. (Figure 24)

The 18 month follow-up demonstrated excellent emergence profile and implant stability with no noted mobility. The emergence profile is the axial contour of the natural tooth or prosthetic crown as it relates to the adjacent soft tissue, as a good emergence profile is important to prevent plaque being trapped. (Figure 25)

Discussion

Dental implants in companion animals should be considered experimental under real- world conditions strictly due to the lack of clinical case series documenting success with long- term follow-up. However, since nearly all the human implantology research has been performed on dogs and cats, there is ample experimental documentation of use in these species. Some veterinarians have recommended that under no circumstances should dental implants be placed in dogs and cats due to a number of reasons including a lack of any formal training programs in implantology. The authors would agree that most veterinarians have little or no training in dental implant placement and would also agree that the placement of dental implants without any formal and rigorous training carries a number of unacceptable risks to the pet and the owner. The cost of implant hardware and diagnostic tools is also a consideration. In many cases, the principal author is placing immediate implants with the future option of the crown restoration being done by utilizing complete

digital treatment planning (compared to older methods of direct wax-ups). With digital treatment planning, the laboratory creates the soft tissue model and subsequent castings utilizing advanced computer-aided techniques with extraoral scanning and CAD/CAM design. This computer-aided process provides more precise restorative results than the wax/cast traditional methods employed in the past.

In humans, placement and restoration of dental implants is regarded as a very predictable procedure with long-term survival of implant/crowns if maintenance protocols are strictly followed. As with any procedure performed in companion animals, there has to be a detailed discussion with the pet's owner to obtain informed consent. Based on this information and the predictability of a particular procedure, it is up to the owner to make the final decision. Other treatment options need to be discussed with the owner, and when available, success rates should be incorporated into this discussion. Currently, success rates of dental implants and some other dental procedures in companion animals have not been well established. It must be said that most animals can adequately manage without teeth and that tooth extraction is a predictable procedure (but not always complication free) when dealing with a compromised tooth. Some of the risks and complications associated with dental implants can include perforation into an anatomical structure or space with endosseous drills or the implant, post-operative bleeding, swelling, or infection causing early loss of the implant.

In both cases described here, detailed postoperative instructions were discussed and home care directives were provided. This included type of food to be fed and avoidance of hard play toys. Alteration in the patient's diet to soft foods and avoiding dry food during the initial 4 to 6 weeks following restoration of the implant allowed the patient to adapt to having the tooth for function. Dry cat food was then reintroduced to the diet. These dietary recommendations allow progressive loading of the implant, providing increasing stimulation to the bone surrounding the implant and its restoration and avoid accidental overloading. A lack of adequate training of the clinician would be considered an important risk factor when placing dental implants. Pain after implant placement, at least in man, is described as being generally mild and decreasing over time.⁸ It is the opinion of the authors that this would be also true in companion animals, and the degree of pain that would be expected in implant placement is similar to that experienced following a surgical tooth extraction. Appropriate management of pain and potential infection is warranted when placing dental implants.

Antibiotics given in food or given orally on opposite side of the surgical site was considered safer and more practical than daily home care of the actual surgical site, since most cats will not be still for daily home care of a painful surgical site. Therefore, antibiotics were prescribed for the initial few days following implant placement to keep oral bacteria at a lower level, hopefully decreasing potential for initiation of peri-implantitis before the incision has healed.

Dental implants are not an inexpensive treatment, but in both of these cases, the owners were presented with the available treatment options and the owners made their decision to proceed with the implant placement and subsequent prosthetic restoration. Home care may be an important component of success. The patient in case 1 received exceptional home care, including daily soft brushing with a periodontal brush to keep the gingival margin and crown clean. The patient in case 2 received soft brushing with a water-soaked gauze pad no more than twice weekly.

Conclusion

Dental implants were a viable long-term treatment option in the 2 cats described in this article. The best approach seems to be immediate implant placement at the time of extraction to maintain the surrounding osseous structures and prevent collapse of the labial buccal plate that may result when a delayed placement approach is undertaken.

With careful treatment planning and informed owner consent, implants placed into the canine area to replace a fractured or badly damaged tooth can restore the feline to normal function. Thus far, the authors have placed 30 implants in 15 feline patients (14 of which have been restored), monitoring these cases up to a three year period and no integration failures have been observed to date.

Long-term results have shown implants and crown restorations can be maintained without adverse periodontal sequela or crown fracture. Continued follow-up of these cases is ongoing. ■

References:

1. Polizzi P, Runder U, Goene R, et al. Immediate and delayed implant placement into extraction sockets: a five year report. *Clin Implant Dent Relat Res.* 2000;2(2):93-99.
2. Trisi P, Perfetti G, Baldoni E, et al. Implant micromotion is related to peak insertion torque and bone density. *Clin Oral Implants Res.* 2009;20(5):467-471.
3. Perren SM, Huggler A, Russenberger M, et al. The reaction of cortical bone to compression. *Acta Orthop Scand Suppl.* 1969;125:19-29.
4. Trisi P, Todisco M, Comsolio U, Travaglini D. High versus low implant torque: a histologic, histomorphometric, and biomedical study in sheep mandible. *Int J Oral Maxillofac Implants.* 2011; 26(4):837-849.
5. Huwais S, Meyer EG. A novel osseous densification approach in implant osteotomy preparation to increase bio mechanical primary stability, bone mineral density and bone-to- implant contact. *Int J Oral Maxillofac Implants.* 2017;32(1):27-36.
6. Rieder C. Customized implant abutment copings to achieve bio-logic mechanical and esthetic objectives. *Int J Periodont Restorative Dent.* 1996;16(1):20-29.
7. Chiche FA, Leriche MA. Multidisciplinary implant dentistry for the improved aesthetics and function. *Pract Periodontics Aesthet Dent.* 1998;10(2):177-186.
8. Al-Khabbaz A, Griffin T, Al-Shammari K. Assessment of pain associated with the surgical placement of dental implants. *J Periodontol.* 2007;78(2):239-246.